Esthetic Outcome Evaluation of Maxillary Anterior Single-Tooth Bone-Level Implants with Metal or Ceramic Abutments and Ceramic Crowns

Burçin Akoğlu Vanlıoğlu, DDS[1]/Erkut Kahramanoğlu, DDS, PhD[2]/
Coşkun Yıldız, DDS, PhD[3]/Yaşar Özkan, DDS[4]/Yasemin Kulak-Özkan, DDS[5]

Purpose: *The aim of this study was to evaluate the treatment outcome of implants placed in the maxillary anterior segment.* ***Materials and Methods:*** *Patients were treated with bone-level implants (Straumann Bone Level Implant, Institut Straumann) that supported all-ceramic single crowns and were followed for 2 to 4 years. Titanium or ceramic abutments were used according to the quality of the soft tissue at each site. Esthetic parameters were recorded to assess treatment outcomes. Pink esthetic scores (PES) and white esthetic scores (WES) were used to evaluate the esthetic outcome of anterior single-tooth implant-supported crowns. Patient satisfaction was also evaluated by means of a questionnaire.* ***Results:*** *Fifty-five implants were placed in 47 patients. At the recall examinations, all implants were confirmed to have successfully integrated and demonstrated healthy peri-implant soft tissues, as documented by generally accepted clinical parameters. Overall, the esthetic results were considered favorable, and there were no significant differences between restorations with ceramic or titanium abutments. WES values were slightly superior to PES values. None of the implants had mucosal recession.* ***Conclusion:*** *Objective and subjective evaluation of maxillary bone-level implants in the esthetic zone yielded satisfactory results. Pleasing esthetic outcomes and stable facial soft tissues were achieved.* Int J Oral Maxillofac Implants 2014;29:1130–1136. doi: 10.11607/jomi.3439

Restoring missing teeth in the anterior maxilla with implants is particularly challenging, because this is a highly visible area that frequently presents anatomical challenges for implant placement, such as insufficient available bone volume and thin soft tissue. Soft tissue esthetics represent a major aspect of implant success and may be a main motivating factor for a patient to undergo implant therapy in the esthetic zone.[1,2] Furhauser et al[3] proposed an index, termed the pink esthetic score (PES), which focused on the soft tissue aspects of an anterior implant restoration. Belser et al[1] modified the previously published PES and proposed an implant restoration index, the white esthetic score (WES), for analyzing a single-tooth implant. The PES evaluates the mesial papilla, distal papilla, curvature of the facial mucosa, level of the facial mucosa, and root convexity/soft tissue color and texture at the facial aspect of the implant site as five variables. A score of 2, 1, or 0 is assigned to each of five PES parameters. Thus, in case of an implant restoration, a maximum total PES of 10 is possible. The WES focuses on the visible part of the implant restoration itself and is based on the five following parameters: general tooth form; outline and volume of the clinical crown; color, which includes the assessment of hue and value; surface texture; and translucency and characterization. A score of 2, 1, or 0 is assigned to each parameter. Thus, in the case of an implant restoration, a maximum total WES of 10 is possible.

The bone support and the soft tissue dimensions around an implant-supported single-tooth restoration are suggested to be important factors for the esthetic outcome of implant therapy.[1] Other factors that influence the position of the soft tissue contours surrounding implant-supported restorations are crown dimensions, height of the proximal contacts, tooth-implant distances, and implant diameter.

The most common esthetic complication is gingival recession that exposes the implant/abutment junction, with one study reporting that up to 61% of cases had at least 1 mm of gingival recession on the facial

[1]Associate Professor, University of Marmara, Department of Prosthetic Dentistry, Istanbul, Turkey.
[2]Research Assistant, University of Marmara, Department of Prosthetic Dentistry, Istanbul, Turkey.
[3]Assistant Professor, University of Marmara, Department of Prosthetic Dentistry, Istanbul, Turkey.
[4]Professor, University of Marmara, Department of Oral Surgery, Istanbul, Turkey.
[5]Professor and Chairman, University of Marmara, Department of Prosthetic Dentistry, Istanbul, Turkey.

Correspondence to: Dr Burçin Akoğlu Vanlıoğlu, University of Marmara, Department of Prosthodontics, Büyükçiftlik Sokak No. 6, Güzelbahçe, 34365, Nişantaşı, Istanbul, Turkey. Fax: +90-212-246-52-47. Email: drburcinakoglu@hotmail.com

aspect.[4] In addition, poor shade selection for the prosthesis and a lack of interdental papillae may also account for implant esthetic failures.

Thin soft tissue biotypes are found in approximately 15% of patients and are characterized by thin, delicate soft tissue; minimal keratinized gingiva; and pronounced soft tissue scalloping.[5] Because these patients are more likely to respond to periodontal insult with recession, additional care must be taken to ensure esthetic success during implant treatment.

This study evaluated treatment outcomes for implant-supported all-ceramic single-crown restorations in the maxillary esthetic zone. Objective assessments were performed by means of the PES and WES, and subjective evaluations of patient satisfaction were also done.

MATERIALS AND METHODS

Patients who had been treated consecutively between 2008 and 2010 with single implant-supported restorations in the maxillary esthetic zone were recruited for this study. Information was given to each patient about treatment alternatives. All patients were treated at the University of Marmara, Department of Oral Surgery and Department of Prosthetic Dentistry, and signed the appropriate informed consent document, which had been approved by the Institutional Review Board. All subjects were required to be at least 18 years old, able to read and sign the corresponding informed consent document, physically and psychologically able to tolerate conventional surgical and restorative procedures, and willing to return for follow-up examinations as outlined by the investigators. Exclusion criteria were systemic diseases that could alter the integration of dental implants, pregnancy, or smoking of more than 10 cigarettes per day.

Diagnostic impressions were made with irreversible hydrocolloid (Phase Plus, Zhermack). Impressions were poured with type II dental stone (GC Fujirock EP, GC Europe). Periapical and panoramic radiographs were obtained before surgery for all patients.

At the time of implant placement, patients were given local anesthetic (Maxicaine Fort, articaine 80 mg/epinephrine 0.020 mg, VEM). Following confirmation of anesthesia, a slightly palatal crestal incision was made with extensions through the buccal and palatal sulci of the adjacent teeth and a divergent relieving incision at the distal tooth. A minimal mucoperiosteal flap was prepared to expose the alveolar ridge. The alveolar bone was leveled to the implant neck. The shoulder of the implant was placed at a depth of 3 mm apical to the most facial cervical aspect of the prospective clinical crown to ensure a proper emergence profile. All implants were longer than 10 mm and had a diameter of 4.1 mm; dimensions were chosen according to the available bone volume. When part of the implant remained uncovered or when the facial bone wall thickness was less than 2 mm, a local augmentation procedure was performed using the autogenous bone chips collected during implant bed preparation. The implants were not submerged, and appropriate healing screws were selected and placed.

The implants were restored with provisional crowns after a healing period of 8 weeks. During the healing period, patients received etched and bonded fixed partial dentures that avoided potential contact of the intaglio surface with the implant. After 8 weeks, a second implant-supported provisional was fabricated and used to manipulate the soft tissue contours for 2 to 3 weeks. All patients with a thin soft tissue biotype received ceramic abutments (Bone Level Anatomic IPS e.max, Straumann) to avoid unpleasant esthetic results; the other patients received titanium abutments (Bone Level Anatomic, Straumann). All titanium abutments were tightened to 35 Ncm, and all ceramic abutments were tightened to 25 Ncm, as recommended by the manufacturer. For the definitive restorations, pressed lithium disilicate ceramic crowns layered with feldspathic porcelain (IPS e.max Press, Ivoclar Vivadent) were fabricated and cemented using a resin luting agent (Multilink, Ivoclar Vivadent). Prior to cementation, the fit of the restorations was evaluated using a light-body addition silicone material (Affinis, Coltene/Whaledent) to ensure passive fit. The abutments were tightened with the torque driver of the manufacturer.

The prostheses were fabricated with an occlusal scheme that provided simultaneous contact in maximal intercuspation in the tooth and implant-supported fixed partial dentures, canine protection or group function guidance during working side movements according to each patient's existing occlusion, and no interferences during nonworking side movements.

To determine PES and WES, all implant crowns were evaluated clinically and were photographed with the contralateral tooth. For the implant-supported crowns, the photograph was centered at the midline to facilitate subsequent analysis, which is primarily based on symmetry. The photographic approach was slightly modified for any first premolar single-tooth implants located in the maxillary esthetic zone. These standardized photographs had to include a full representation of the second premolar, which served as the reference.

A score of 2, 1, or 0 was assigned to each PES/WES parameter. The highest possible combined PES/WES score was 20, which represented peri-implant soft tissue conditions and a comparison of the clinical single-tooth crown to the contralateral tooth. The threshold

of clinical acceptability was set at 6 for each of PES and WES (total score of 12).[2]

The PES/WES analyses were performed by two experienced prosthodontists who had not been involved in the prosthetic treatment of the patients enrolled in the study. To reduce bias and to ensure optimum reproducibility, the evaluation was carried out twice on different days. If differences arose for any particular case, a short discussion ensued until consensus between the two examiners was reached.

Patient satisfaction with implant surgery and prosthetic treatment was evaluated with a self-administered questionnaire after prosthetic treatment and annually thereafter. The questions addressed the patient's satisfaction with the treatment outcome from an esthetic point of view as excellent, good, satisfactory, or poor.

The implemented statistical analysis sought to detect any significant correlations between the total PES/WES scores and patient questionnaire responses. To compare patient satisfaction responses before and after treatment, the Wilcoxon signed rank test was used. To test reliability, the intraexaminer and interobserver agreement and the weighted Cohen κ were calculated. All tests were performed using statistical software (SPSS, version 11.5, SPSS Inc) at a level of significance of $P = .05$.

RESULTS

Fifty-five implants were placed in 47 patients, who had been treated consecutively between 2008 and 2010. The group consisted of 23 female and 24 male patients, with a mean age of 33.43 years (range: 20 to 59 years). The implant sites included 18 central incisor, 16 lateral incisor, 5 canine, and 16 first premolar positions. No patient dropouts were recorded during the observation period. Forty-five implants were restored with titanium abutments, and the other 10 implants were restored with ceramic abutments according to the patients' soft tissue biotypes.

All patients were recalled in 2012 as part of their routine annual recall program. At that time, 7 implants had been in place for 4 years, 30 implants for 3 years, and 18 implants for 2 years since the restoration was completed.

A detailed analysis of the relevant clinical and radiographic parameters of this retrospective study will be reported in a separate publication.

The frequency of intraobserver and interobserver agreement was over 70% for all observations. The PES/WES scores of the 55 examined single-tooth implants are summarized in Table 1. The mean total PES/WES at baseline was 15.33 ± 1.73 (range, 12 to 19) (Table 2). None of the anterior single-tooth implants had an overall score < 12, which would have indicated a treatment outcome below the defined threshold of clinical acceptability. The differences in the mean PES and WES given by the two prosthodontists at baseline and follow-up were not statistically significant.

The mean total PES was 9.03 ± 0.93 (range, 7 to 10) at 3 years. The PES parameter facial mucosa curvature (1.69 ± 0.47) had the highest mean values at baseline, whereas root convexity was the most difficult to satisfy. For the papillary area, mean scores of 1.22 ± 0.42 for the mesial papilla and 1.3 ± 0.46 for the distal papilla at baseline increased to 1.65 ± 0.48 and 1.56 ± 0.5, respectively, at the last recall. For the total PES, none of the 55 single-tooth implants scored < 6 (Table 3a; Figs 1 and 2).

For the WES, the mean total was 8.15 ± 1.11 (range, 6 to 10) (Table 3b). Of the 55 implant crowns examined, none of them scored below the threshold of 6. There were no statistically significant differences between all-ceramic crowns with metal vs ceramic abutments.

Linear regression analysis did not reveal any statistically significant correlations between the total PES/WES and patients' responses to the questionnaire. Twenty patients evaluated the esthetics of the restorations as excellent, whereas none of them scored as satisfactory or poor.

DISCUSSION

Esthetic-outcome assessment has been an emerging area of focus in implant dentistry. To sustain an esthetic appearance, it is essential to consider the characteristics of the surrounding soft and hard tissues.[1] The variables "root convexity" and "soft tissue color and texture" showed the lowest mean scores of all five PES parameters. It might be difficult to obtain a maximum score for these parameters because together they consist of three different requirements to be fulfilled. The level of facial mucosa had the highest level of success. There was no statistically significant correlation between PES and WES.

Belser et al[1] evaluated the esthetic outcome of maxillary anterior single-tooth implants using WES/PES. They reported that PES (mean of 7.8) were clearly higher than the corresponding WES (mean of 6.9), but more than 20 different technicians had fabricated the restorations that they analyzed. In the current study, only one experienced technician created all the restorations, and the mean WES of this study is higher than that of Belser et al. The statistical analysis did reveal a statistically significant correlation between patients' esthetic perception and dentists' perception of the anterior tooth. On the other hand, for the first

Table 1 PES and WES Scores for Assessment at Baseline and Follow-up

Patient no.	Location*	Baseline			6 mo			1 y			2 y			3 y			4 y		
		PES	WES	Total	PES	WES	Total	PES	WES	Total	PES	WES	Total	PES	WES	Total	PES	WES	Total
1	21	6	10	16	6	10	16	6	10	16	6	10	16	8	10	18			
2	21	6	8	14	6	8	14	6	8	14	7	8	15	7	8	15			
3	22	9	8	17	9	8	17	9	8	17	9	8	17	9	8	17			
4	23	7	7	14	8	7	15	8	7	15	8	7	15	8	7	15			
5	14	6	7	13	6	7	13	6	7	13	7	7	14	8	7	15			
6	21	6	8	14	6	8	14	6	8	14	6	8	14	7	8	15			
7	12	7	8	15	7	8	15	7	8	15	9	8	17	9	8	17			
8	22	7	8	15	7	8	15	7	8	15	9	8	17	9	8	17			
9	13	9	9	18	9	9	18	9	9	18	9	9	18	9	9	18			
10	24	6	9	15	6	9	15	7	9	16	7	9	16	8	9	17			
11	14	6	9	15	6	9	15	7	9	16	7	9	16	8	9	17			
12	34	6	9	15	6	9	15	6	9	15	7	9	16	8	9	17			
13	44	6	9	15	6	9	15	7	9	16	7	9	16	8	9	17			
14	12	7	9	16	7	9	16	7	9	16	8	9	17	8	9	17			
15	24	8	8	16	8	8	16	8	8	16	8	8	16						
16	33	6	7	13	6	7	13	6	7	13	7	7	14	7	7	14			
17	11	8	8	16	8	8	16	8	8	16	8	8	16	8	8	16			
18	12	6	8	14	6	8	14	6	8	14	7	8	15	7	8	15			
19	13	7	8	15	7	8	15	7	8	15	8	8	16	8	8	16			
20	12	7	7	14	7	7	14	7	7	14	7	7	14	7	7	14			
21	21	6	7	13	6	7	13	6	7	13	7	7	14	7	7	14			
22	24	6	8	14	6	8	14	6	8	14	8	8	16						
23	21	7	8	15	7	8	15	7	8	15	8	8	16	8	8	16			
24	21	7	7	14	7	7	14	7	7	14	7	7	14	7	7	14			
25	13	7	9	16	7	9	16	8	9	17	8	9	17						
26	21	8	10	18	8	10	18	8	10	18	8	10	18						
27	22	7	8	15	7	8	15	7	8	15	7	8	15						
28	11	6	10	16	6	10	16	6	10	16	7	10	17	7	10	17			
29	14	6	8	14	6	8	14	6	8	14	8	8	16	8	8	16	8	8	16
30	31	7	7	14	7	7	14	7	7	14	7	7	14	7	7	14			
31	12	9	9	18	9	9	18	9	9	18	10	9	19	10	9	19			
32	24	9	9	18	9	9	18	9	9	18	10	9	19	10	9	19			
33	21	7	8	15	7	8	15	7	8	15	7	8	15	7	8	15			
34	11	7	6	13	7	6	13	8	6	14	8	6	14	8	6	14	8	7	15
35	12	7	6	13	7	6	13	8	6	14	8	6	14	8	6	14	8	6	14
36	12	7	6	13	7	6	13	8	6	14	9	6	15	9	6	15			
37	22	7	6	13	7	6	13	8	6	14	9	6	15	9	6	15			
38	24	8	8	16	8	8	16	8	8	16	8	8	16						
39	44	8	8	16	8	8	16	8	8	16	8	8	16						
40	11	6	8	14	6	8	14	6	8	14	6	8	14	7	8	15	7	8	15
41	21	10	9	19	10	9	19	10	9	19	10	9	19	10	9	19	10	9	19
42	12	8	10	18	8	10	18	8	10	18	10	10	20						
43	22	9	7	16	9	7	16	9	7	16	9	7	16	9	7	16	9	7	16
44	11	6	6	12	6	6	12	6	6	12	6	6	12						
45	14	10	8	18	10	8	18	10	8	18	10	8	18						
46	12	7	10	17	7	10	17	9	10	19	9	10	19						
47	21	7	8	15	7	8	15	7	8	15	7	8	15						
48	24	8	8	16	8	8	16	8	8	16	8	8	16	8	8	16			

Table 1 *continued* PES and WES Scores for Assessment at Baseline and Follow-up

Patient no.	Location*	Baseline			6 mo			1 y			2 y			3 y			4 y		
		PES	WES	Total	PES	WES	Total	PES	WES	Total	PES	WES	Total	PES	WES	Total	PES	WES	Total
49	11	7	10	17	7	10	17	7	10	17	7	10	17						
50	14	10	9	19	10	9	19	10	9	19	10	9	19						
51	14	6	10	16	6	10	16	7	10	17	8	10	18						
52	21	6	8	14	6	8	14	6	8	14	6	8	14	7	8	15	7	8	15
53	11	8	8	16	8	8	16	9	8	17	9	8	17						
54	22	6	8	14	6	8	14	6	8	14	6	8	14						
55	12	9	9	18	9	9	18	9	9	18	9	9	18						

*FDI tooth-numbering system.

Table 2 Mean PES and WES (Variables and Totals) for Implant Restorations at Baseline and Follow-up

Time	PES				WES				Total			
	Max	Min	Mean	SD	Max	Min	Mean	SD	Max	Min	Mean	SD
Baseline	10	6	7.18	1.19	10	6	8.15	1.11	19	12	15.33	1.73
6 mo	10	6	7.2	1.19	10	6	8.15	1.11	19	12	15.35	1.72
1 y	10	6	7.42	1.2	10	6	8.15	1.11	19	12	15.56	1.73
2 y	10	6	7.87	1.17	10	6	8.15	1.11	20	12	16.02	1.73
3 y	10	7	8.03	0.93	10	6	7.92	1.06	19	14	15.95	1.51
4 y	10	7	8.14	1.07	9	6	7.57	0.98	19	14	15.71	1.60

premolar, the statistical analysis did not reveal any statistically significant correlations between patients' esthetic perception and dentists' perception, as mentioned in several other studies.[6] The current findings confirm the idea that patients' esthetic perception of dental restorations may differ significantly according to tooth region.

Gallucci et al[7] reported esthetic outcomes with porcelain-fused-to-ceramic and all-ceramic single-implant crowns retained by 20 Straumann Standard Plus implants. They found no statistically significant differences in the objective measurements between the test and control groups. Minor chipping of the ceramic veneering material was observed in two patients in their control group. The mean difference for all groups in objective parameters revealed an increase of papilla height between time points. A slight recession (0.26 mm) of the peri-implant mucosal margin at the implant site was observed between 1 and 2 years. Mean values for PES and WES were 13.9 and 13.1 for the porcelain-fused-to-metal group and the all-ceramic group, respectively. In this study, no statistically significant differences were observed when objective esthetic parameters were compared between ceramic and titanium abutments. Studies indicate that the presence of papilla adjacent to the implant restoration seems to be dictated by the attachment level of the adjacent teeth and the horizontal implant-tooth distance.[8–10] In this study, no papilla loss was observed in any sites. This may be a result of the implant-abutment connection of the implant system used and the attachment level of the adjacent teeth.[1]

Meijndert and colleagues[11] reported that only 66% of single-implant crowns in 99 patients were rated as acceptable by a prosthodontist, despite high patient satisfaction scores. None of the 55 single-tooth implants in this study scored < 6, which confirms the high predictability of the surgical protocol and proximity to a tooth with optimal alveolar bone. In the present study, except for the mesial and distal papillae, the combined variables of root convexity/soft tissue color and texture were slightly less favorable than the other parameters. This might reflect the difficulty in attaining a maximum score for this parameter because three different requirements must be met.

PES may change over time and can be a useful tool for monitoring long-term soft tissue alterations. Furhauser et al[3] reported that the color of the peri-implant soft tissue matched that of the reference tooth in no more than about one-third of cases and showed major discrepancies in 20% of cases. The level of the soft tissue margin and the color of the peri-implant soft tissue fared worst in their assessments. They mentioned that tooth-colored ceramic abutments would appear to play an important role.

In general, a patient with the combination of a high lip line and a thin gingival biotype is extremely difficult to treat and should be considered an anatomical

Figs 1a and 1b Clinical aspects of single-tooth implants in the lateral incisor locations with high PES/WES.

Table 3a Mean PES Scores at Baseline and Recall

Parameter	Max	Min	Mean	SD
Mesial papilla				
Baseline	2	1	1.22	0.42
Recall	2	1	1.65	0.48
Distal papilla				
Baseline	2	1	1.18	0.39
Recall	2	1	1.56	0.50
Curvature of facial mucosa				
Baseline	2	1	1.69	0.47
Recall	2	1	1.62	0.49
Level of facial mucosa				
Baseline	2	1	1.36	0.49
Recall	2	1	1.53	0.50
Roof convexity				
Baseline	1	0.5	0.80	0.25
Recall	1	0.5	0.80	0.25
Soft tissue color and texture				
Baseline	1	0.5	0.82	0.25
Recall	1	0.5	0.81	0.24

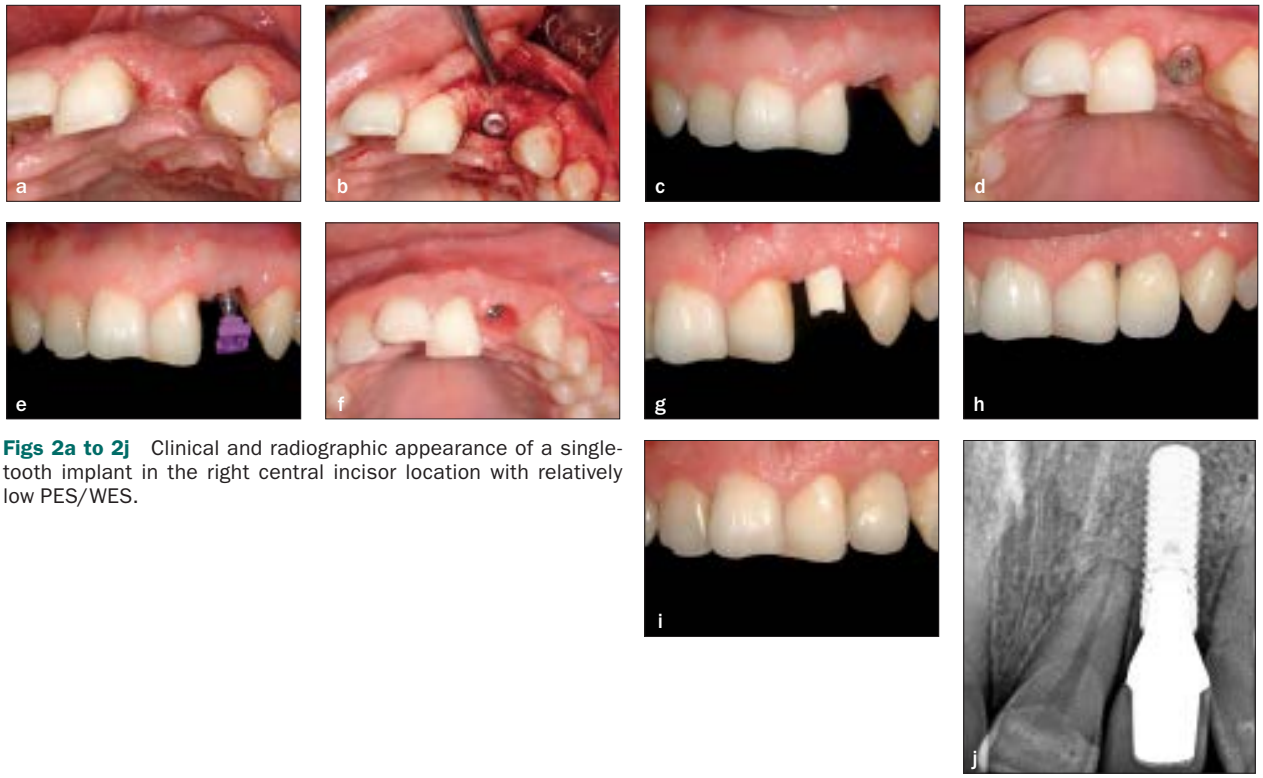

Figs 2a to 2j Clinical and radiographic appearance of a single-tooth implant in the right central incisor location with relatively low PES/WES.

risk. In this study, Straumann Anatomic IPS e.max abutments were used for patients with a thin soft tissue biotype. This might be a reason that the overall scores were higher than other studies.

Cardaropoli et al[10] reported an increase in the thickness of the labial mucosa at crown placement followed by a slight recession at 1 year with Brånemark implants that had osseointegrated for 6 months. They reported a mean apical displacement of the labial soft tissue margin of 0.6 mm and a papilla fill of 50% at a frequency of 32% at crown placement and 86% at 1 year. In contrast, Cooper and colleagues[12] reported stability of the facial soft tissue contour at the interface of conus design implants and abutments throughout a 3-year

Table 3b Mean WES Scores at Baseline and Recall

Parameter	Max	Min	Mean	SD
Tooth form/volume/outline				
Baseline	4	2	3.36	0.93
Recall	4	2	3.36	0.93
Translucency/characterization				
Baseline	2	1	1.44	0.5
Recall	2	1	1.44	0.5
Surface texture				
Baseline	2	1	1.58	0.5
Recall	2	1	1.56	0.5
Color				
Baseline	2	1	1.69	0.47
Recall	2	1	1.69	0.47

period. In the current study, there was no mucosal recession and the rate of the papilla fill was higher. The early loading of bone-level implants with a platform-switching concept that was done in this study might have encouraged the soft tissue modeling.

The linear regression analysis did not reveal any statistically significant correlations between the total PES/WES and patients' responses to the questionnaire. This confirms the fact that patients' perceptions of dental restorations from an esthetic point of view may differ significantly from those of dental professionals. In comparing patients' and clinicians' judgments of the esthetic outcome of implant-supported single-tooth replacements, it is concluded that the esthetic outcomes were appreciated more by the patients than by the prosthodontists.

CONCLUSIONS

Objective and subjective evaluations of maxillary implants restored with titanium or ceramic abutments and all-ceramic crowns in the esthetic zone yielded satisfactory results. The follow-up revealed pleasing esthetic outcomes and stable facial soft tissues.

ACKNOWLEDGMENTS

The authors reported no conflicts of interest related to this study.

REFERENCES

1. Belser UC, Grütter L, Vailati F, Bornstein MM, Weber HP, Buser D. Outcome evaluation of early placed maxillary anterior single-tooth implants using objective esthetic criteria: A cross-sectional, retrospective study in 45 patients with a 2- to 4-year follow-up using pink and white esthetic scores. J Periodontol 2009 Jan;80:140–151.
2. Pjetursson BE, Karoussis I, Burgin W, Bragger U, Lang NP. Patients' satisfaction following implant therapy. A 10-year prospective cohort study. Clin Oral Implants Res 2005;16:185–193.
3. Furhauser R, Florescu D, Benesch T, Mailath G, Watzek G. Evaluation of soft tissue around single-tooth implant crowns: The pink esthetic score. Clin Oral Implants Res 2005;16:639–644.
4. Oates TW, West J, Jones J, et al. Long-term changes in soft tissue height on the facial surface of dental implants. Implant Dent 2002;11:272–279.
5. Olsson M, Lindhe J. Periodontal characteristics in individuals with varying form of the upper central incisors. J Clin Periodontol 1991;18:78–82.
6. An KY, Lee JY, Kim SJ, Choi JI. Perception of maxillary anterior esthetics by dental professionals and laypeople and survey of gingival topography in healthy young subjects. Int J Periodontics Restorative Dent 2009;29:535–541.
7. Gallucci GO, Grütter L, Nedir R, Bischof M, Belser UC. Esthetic outcomes with porcelain-fused-to-ceramic and all-ceramic single-implant crowns: A randomized clinical trial. Clin Oral Implants Res 2011;22:62–69.
8. Grunder U. Stability of the mucosal topography around single-tooth implants and adjacent teeth: 1-year results. Int J Periodontics Restorative Dent. 2000;20:11–17.
9. Choquet V, Hermans M, Adriaenssens P, Daelemans P, Tarnow DP, Malevez C. Clinical and radiographic evaluation of the papilla level adjacent to single-tooth dental implants. A retrospective study in the maxillary anterior region. J Periodontol 2001;72:1364–1371.
10. Cardaropoli G, Lekholm U, Wennström JL. Tissue alterations at implant-supported single-tooth replacements: A 1-year prospective clinical study. Clin Oral Implants Res 2006;17:165–171.
11. Meijndert L, Meijer HJ, Stellingsma K, et al. Evaluation of aesthetics of implant-supported single-tooth replacements using different bone augmentation procedures: A prospective randomized clinical study. Clin Oral Implants Res 2007;18:715–719.
12. Cooper LF, Ellner S, Moriarty J, et al. Three-year evaluation of single-tooth implants restored 3 weeks after 1-stage surgery. Int J Oral Maxillofac Implants 2007;22:791–800.